ECG & Arrhythmias

Measurements

- Heart rate
- PR interval
- QRS duration
- QT interval
- QRS axis

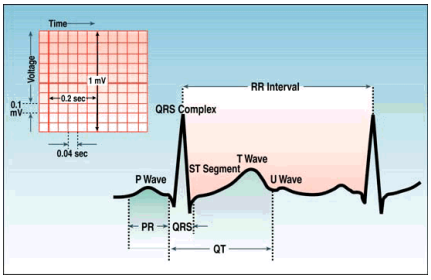

PR Interval

- Normal: 0.12 - 0.20s
- Short PR: < 0.12s

Preexcitation syndromes:

- WPW (Wolff-Parkinson-White) Syndrome: An accessory pathway connects the right atrium to the right ventricle or the left atrium to the left ventricle, and this permits early activation of the ventricles (*delta* wave) and a short PR interval.
- LGL (Lown-Ganong-Levine): An AV nodal bypass track into the His bundle exists, and this permits early activation of the ventricles without a *delta*-wave because the ventricular activation sequence is normal.

Prolonged PR: >0.20s

- First degree AV block (PR interval usually constant)
- Second degree AV block (PR interval may be normal or prolonged; some P waves do not conduct)

Type I (Wenckebach): Increasing PR until nonconducted P wave occurs

Type II (Mobitz): Fixed PR intervals plus nonconducted P waves

- AV dissociation: Some PR's may appear prolonged, but the P waves and QRS complexes are dissociated

QRS Duration

- Normal: 0.06 - 0.10s
- Prolonged QRS Duration (>0.10s):

QRS duration 0.10 - 0.12s
ICRBBB, ICLBBB, IVCD

QRS duration ≥ 0.12s
LBBB, RBBB, IVCD
VT, Pacemaker rhythm

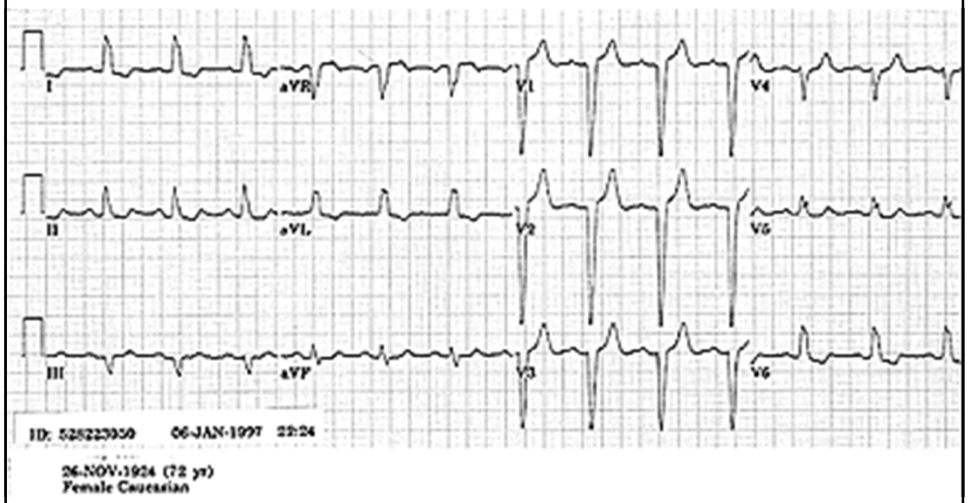

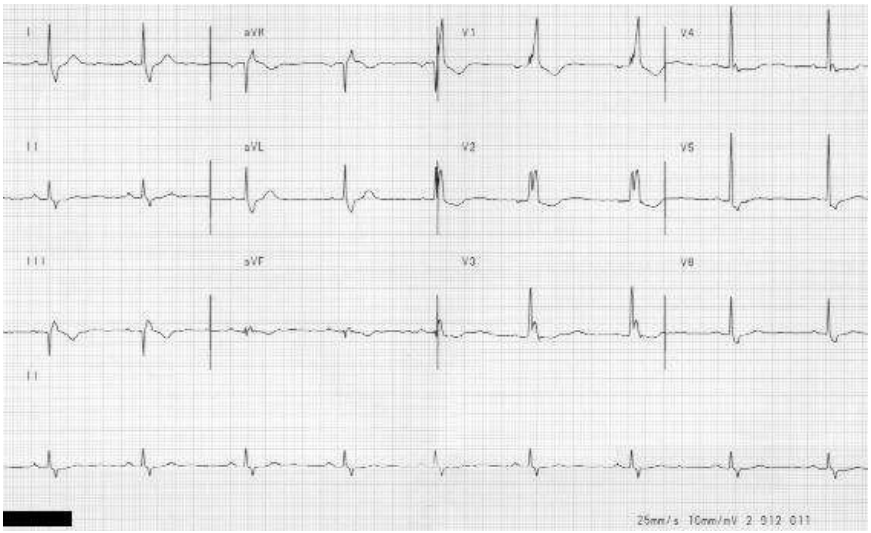

QT Interval

- Normal: heart rate dependent (corrected QT = QT**c** = measured QT ¸ **Bazett's Formula**: QT**c** = (QT)/SqRoot RR (in seconds); upper limit for QT**c** = 0.44 sec)

- Long QT Syndrome - "LQTS" (based on upper limits for heart rate; QT**c** ≥ 0.47 sec for males and ≥ 0.48 sec in females is diagnostic for *hereditary* LQTS in absence of other causes of increased QT)

Long QT Interval

- The QT interval duration is greater than 50% of the RR interval, a good indication that it is prolonged in this patient.
- Although there are many causes for the long QT, patients with this are at risk for malignant ventricular arrhythmias, syncope, and sudden death.

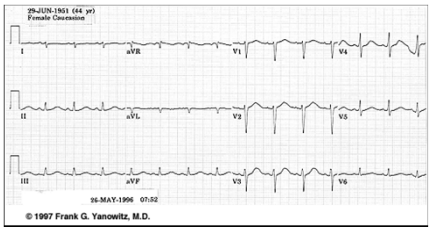

QRS Axis Determination

Normal: -30 degrees to +90 degrees

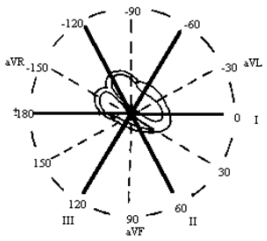

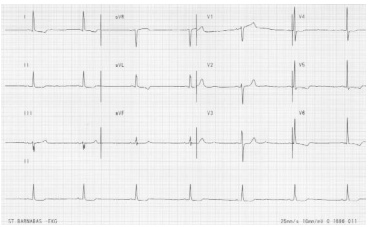

Conduction

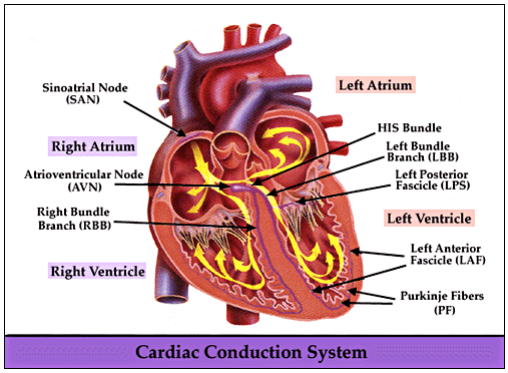

ECG Conduction **Abnormalities**

- Sino-Atrial Exit Block

2**nd** Degree SA Block: this is the only degree of SA block that can be recognized on the surface ECG

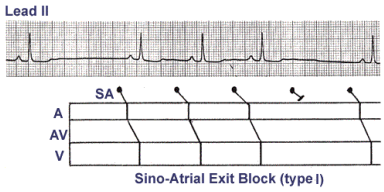

- Atrio-Ventricular (AV) Block
- Intraventricular Blocks

Atrio-Ventricular (AV) Block

- **1st Degree AV Block**: PR interval > 0.20 sec; all P waves conduct to the ventricles.

1st degree AV block (PR = 280 ms)

2nd Degree AV Block

- Type I (Wenckebach) AV block (note the RR intervals in ms duration):

Type I AV block is ***almost always*** located in the AV node, which means that the QRS duration is usually narrow, unless there is preexisting bundle branch disease.

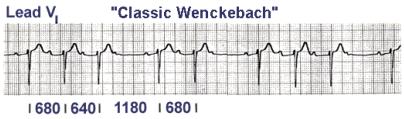

2nd Degree AV Block

- Type II (Mobitz) AV block(note there are two consecutive constant PR intervals before the blocked P wave):

Type II AV block is ***almost always*** located in the bundle branches

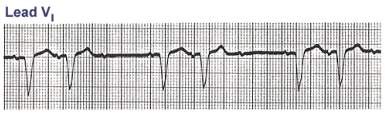

2nd degree AV block (type II) with LBBB

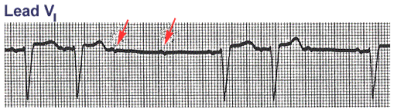

Complete AV Block

- Usually see ***complete AV dissociation*** because the atria and ventricles are each controlled by separate pacemakers
- Narrow QRS rhythm suggests a junctional escape focus for the ventricles with block above the pacemaker focus, usually in the AV node.
- Wide QRS rhythm suggests a ventricular escape focus

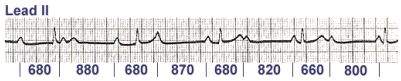

1. What is the diagnosis?
2. Why are the PP intervals alternating?

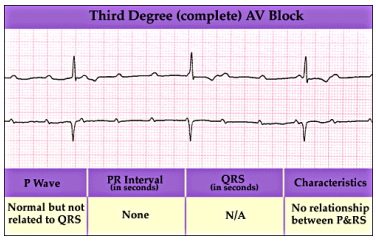

NB

- 1. При обследовании JVP высокие a – wave, сокращение пр. предсердия (cannon a wave), следствие атрио-вентрикулярной диссоциации (полный АВ блок, VT). При AF – нет a-wave.
- 2. Болезнь Лайма – ассоциируется с АВ блоком

Показания для постоянного водителя ритма (class I)

- Симптоматичный АВ блок (II (mobitz II) & III степени
- Asystole $\geq$ 3 сек
- Симптоматичная дисфункция синусового узла (chronotropic incompetence)
- Hypersensitive Carotid Sinus Syndrom

Повторяющиеся потери сознания при стимуляции CS

>3 сек асистола при минимальной стимуляции CS

Экстрасистолы

- Предсердные

- Желудочковые

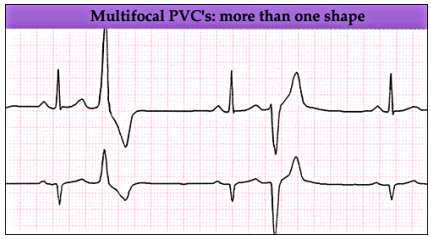

Как правило не требуют лечения

SVT

- Над желудочковая пароксизмальная тахикардия
- Основной симптом – сердцебиение
- Syncope – редко
- Как правило не ассоциируется со структуральными проблемами сердца, за исключение WPW, которое бывает вместе с HOCM, Ebstain's anomaly.
- На ЭКГ – тахикардия с узким QRS (бывают исключения) 160-250 в минуту.
- Большинство зависит от AB узла и реагирует на Vagal maneuvers или на лекарства замедляющие проведение в AB узле.

Short-term Therapy

- **Adenosine** – и лечебное и диагностическое значение.

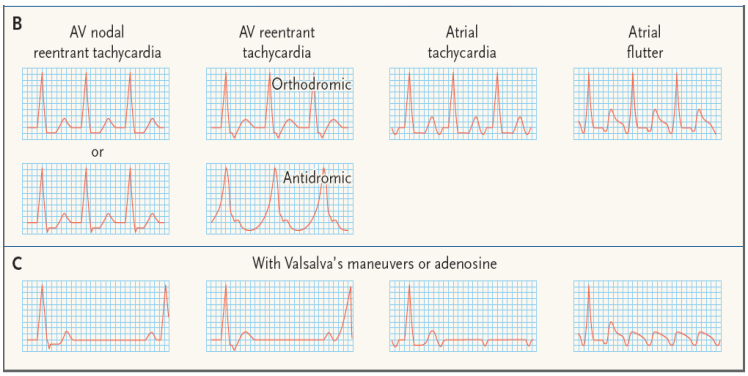

Основной механизм - reentry mechanism

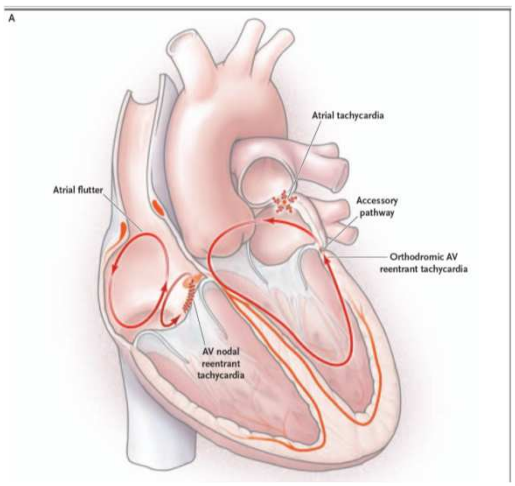

SVT + Wolff–Parkinson–White Syndrome

- Ортодромик и антидромик
- Верапамил, дигоксин, бета-блокаторы и аденозин противопоказаны
- Class I антиаритмики или electrical cardioversion как немедленное лечение
- В последствии – абляция.

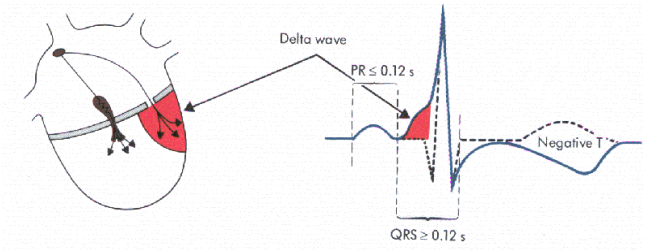

Varying Degrees of Ventricular Preexcitation

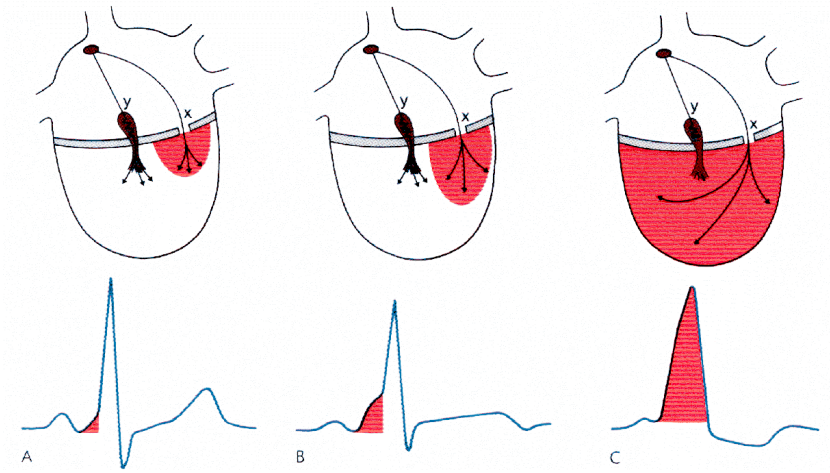

Orthodromic A-V re-entrant tachycardia

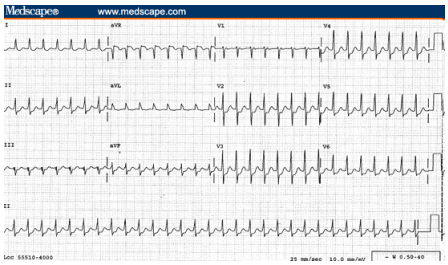

Antidromic AV re-entrant tachycardia

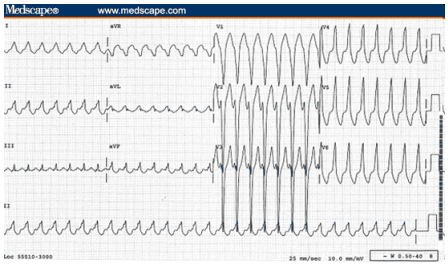

Findings Identifying the Low-Risk Patient

- Block in the AP during exercise
- An anterograde RP of the AP 270 ms during intracardiac or esophageal stimulation
- Finding of intermittent pre-excitation
- Block in the AP after drug administration

Atrial Fibrillation

- Нет P волн на ЭКГ, есть f волны не регулярные, от 350 до 600 в мин. Нерегулярный желудочковый ритм
- Причины алкоголь, гипоксия (заболевания легких), ИБС, RHD, гипертония, ASD, тиреотоксикоз.
- Лечение – Rate & Rhythm control
- Антикоагуляция.

Atrial Flatter – часто связанно с органическим поражение сердца. Волны F – зубья пилы, 250-300 в минуту. Желудочковый ритм зависит от блока.

- Наиболее эффективное лечение electrical cardioversion , далее – абляция.

Atrial Fibrillation

- Atrial activity is poorly defined
- Ventricular response is ***irregularly irregular***
- ***Regular*** ventricular response with A-fib usually indicates <u>complete AV block</u> with an escape or accelerated ectopic pacemaker originating in the AV junction or ventricles

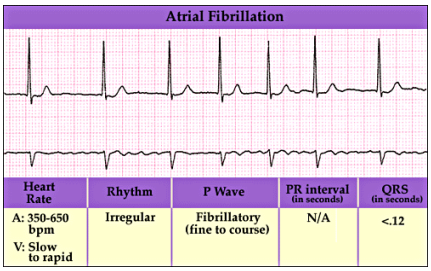

Atrial Flutter

- Regular atrial activity with a "clean" ***saw-tooth*** **appearance in leads II, III, aVF, and usually discrete 'P' waves in lead V1**
- Atrial rate is usually about 300/min
- The ventricular response may be 2:1, 3:1 (rare), 4:1, or irregular depending upon the AV conduction properties and AV node slowing drugs on board (e.g., digoxin, beta blockers).
- Always think "atrial flutter with 2:1 block" whenever there is a regular supraventricular tachycardia ~150 bpm!

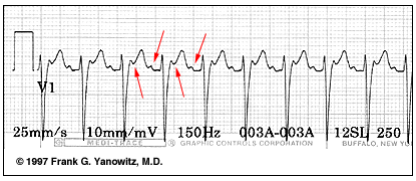

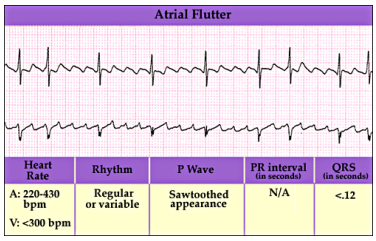

Классификация AF

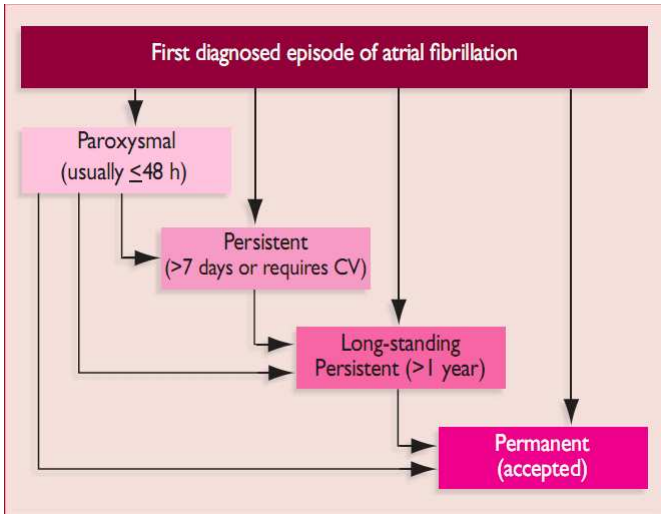

CHA_2DS_2-VASc score

(a) Risk factors for stroke and thrombo-embolism in non-valvular AF	
'Major' risk factors	**'Clinically relevant non-major' risk factors**
Previous stroke, TIA, or systemic embolism Age ≥75 years	Heart failure or moderate to severe LV systolic dysfunction (e.g. LV EF ≤40%) Hypertension - Diabetes mellitus Female sex - Age 65–74 years Vascular disease[a]

(b) Risk factor-based approach expressed as a point based scoring system, with the acronym CHA_2DS_2-VASc (Note: maximum score is 9 since age may contribute 0, 1, or 2 points)	
Risk factor	**Score**
Congestive heart failure/LV dysfunction	1
Hypertension	1
Age ≥75	2
Diabetes mellitus	1
Stroke/TIA/thrombo-embolism	2
Vascular disease[a]	1
Age 65–74	1
Sex category (i.e. female sex)	1
Maximum score	**9**

Подход к антикоагуляции

Table 9 Approach to thromboprophylaxis in patients with AF

Risk category	CHA_2DS_2-VASc score	Recommended antithrombotic therapy
One 'major' risk factor or ≥2 'clinically relevant non-major' risk factors	≥ 2	OAC[a]
One 'clinically relevant non-major' risk factor	1	Either OAC[a] or aspirin 75–325 mg daily. Preferred: OAC rather than aspirin.
No risk factors	0	Either aspirin 75–325 mg daily or no antithrombotic therapy. Preferred: no antithrombotic therapy rather than aspirin.

Желудочковая тахикардия (VT)

- Sustained VT > 30 сек. или коллапс.
- Обычно связанно со структуральным поражением сердца – ИБС с предыдущим ИМ – самая частая причина, CHF, кардиомиопатии, метаболические нарушения, лекарства, long QT syndrome
- Monomorphic & polymorthic
- QRS широкий, больше 100 в мин. AB диссоциация, cannon a wave, вариабельный 1й сердечный тон.
- Верапамил, дигоксин, бета-блокаторы и аденозин противопоказаны.
- Возможно лечение Class I, III, electrical cardioversion
- Прогноз зависит от причины.

Ventricular Tachycardia

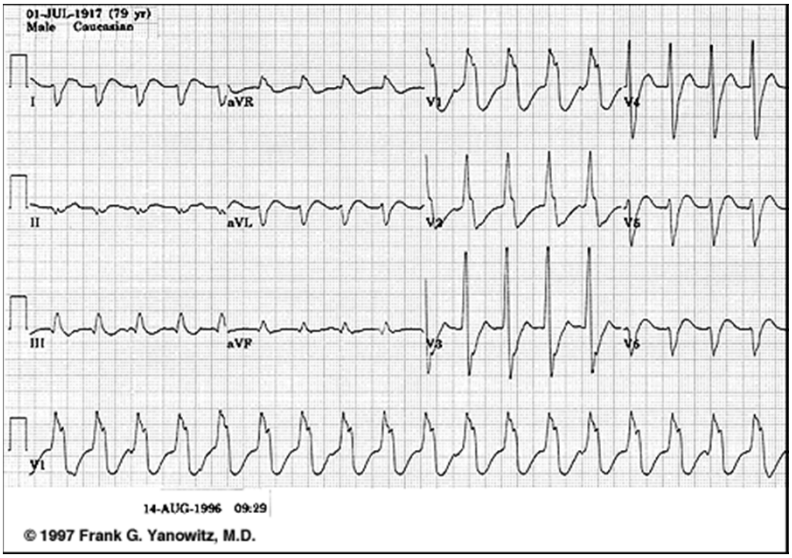

Electrocardiographic findings in monomorphic VT

- *Capture beat:* Occasionally an atrial impulse may cause ventricular depolarisation via the normal conduction system.
- *Fusion beats:* A fusion beat occurs when a sinus beat conducts to the ventricles via the atrioventricular node and fuses with a beat arising in the ventricles.

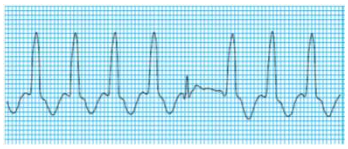

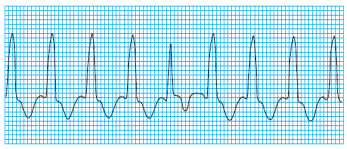

Torsades de pointes tachycardia

- Torsades de pointes (“twisting of points”) – следствие гипокалемии или гипомагнеземии. Обычно QT удлинен до 600 msec.
- Лечение – Сульфат магния.
- Acquired QT prolongation, antiarrhythmic medications (class IA, class 1C, and class III , phenothiazines (eg, haloperidol), cyclic depressants, antihistamines, antimicrobials (Ampicillin, Clarithromycin, Trimethoprim Sulfamethoxazole)
- Клиника – потери сознания, SCD (внезапная смерть)
- Long QT – бывает врожденным (лечение отличается)

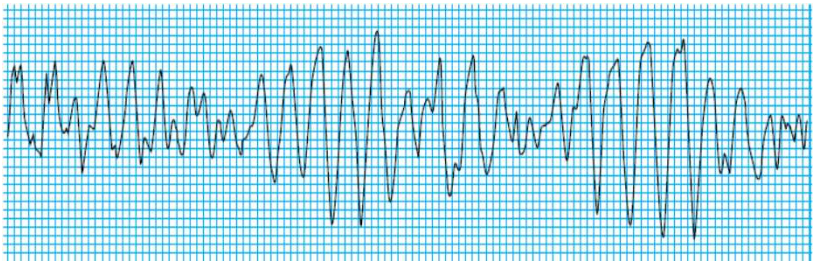

Показания для ICD

- Cardiac arrest из-за VT&VF, без проходящей причины (ОИМ)
- Sust. VT и структуральное заболевание сердца
- Syncope + Sust.VT или VF at EPS
- NSVT + IHD, LVD, MI в анамнезе
- Sust. VT без структ. заболевания не поддающееся лекарственному лечению.
- LV EF<30%, как минимум месяц после ОИМ и 3 месяца после реваскуляризации.

Recognition of Myocardial Infarction

- Hyperacute T wave changes
- Marked ST elevation with hyperacute T wave changes
- Pathologic Q waves, less ST elevation, terminal T wave inversion
- Pathologic Q waves, T wave inversion
- Pathologic Q waves, upright T waves
- Pathologic Q waves are usually defined as duration ≥0.04 s or >25% of R-wave amplitude

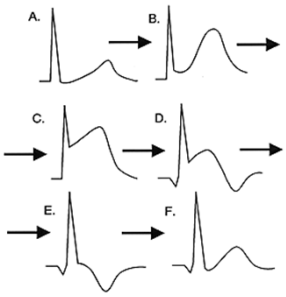

Evolution of Acute MI

Inferior MI

- Pathologic Q waves and evolving ST-T changes in leads II, III, aVF

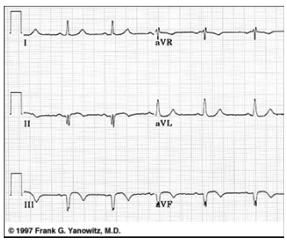

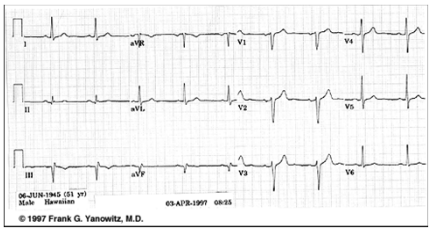

Inferior MI

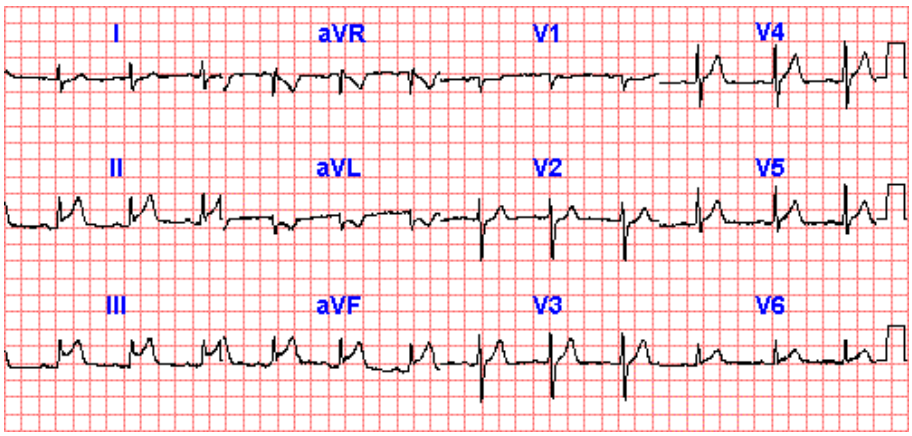

Anterior Family of Q-wave MI's

- Anteroseptal MI - leads V1-V3 (V4)
- Anterior MI (similar changes, but usually V1 is spared; if V4-6 involved call it "anterolateral")
- High Lateral MI (typical MI features seen in leads I and/or aVL)

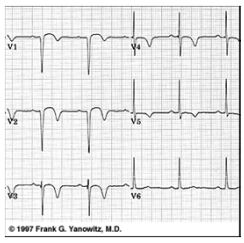

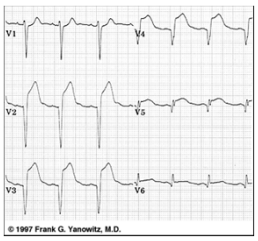

Differential Diagnosis of ST Segment Elevation

- Persistent ST elevation after acute MI suggests ventricular aneurysm
- ST elevation may also be seen as a manifestation of Prinzmetal's (variant) angina (coronary artery spasm)
- ST elevation during exercise testing suggests extremely tight coronary artery stenosis or spasm (transmural ischemia
- Other Causes: LBBB (in right precordial leads with large S-waves), advanced hyperkalemia, hypothermia

Acute Pericarditis

- ST elevation in most leads except aVR
- No reciprocal ST segment depression (except in aVR)
- Unlike "early repolarization", T waves are usually low amplitude, and heart rate is usually increased.
- May see PR segment depression, a manifestation of atrial injury